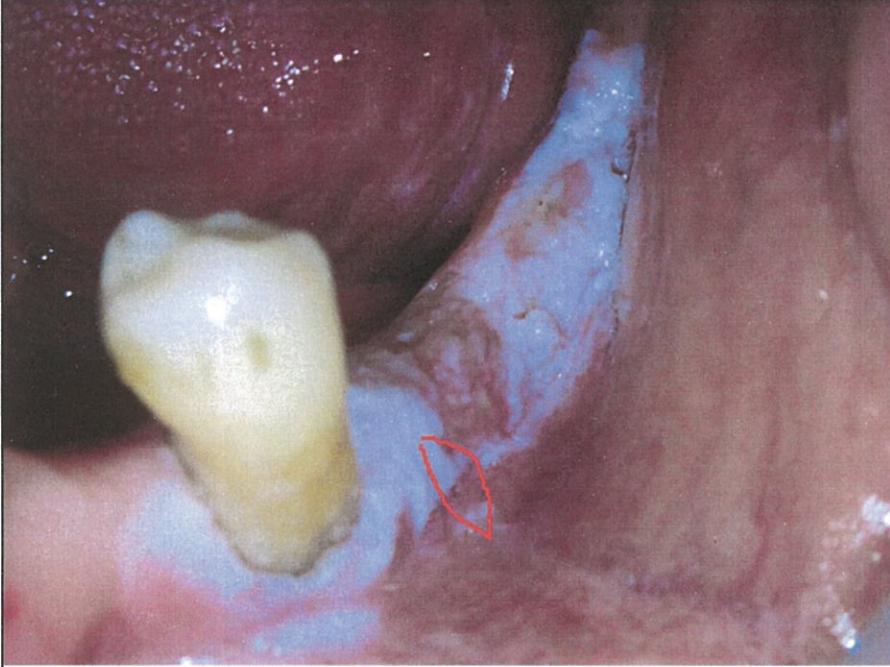
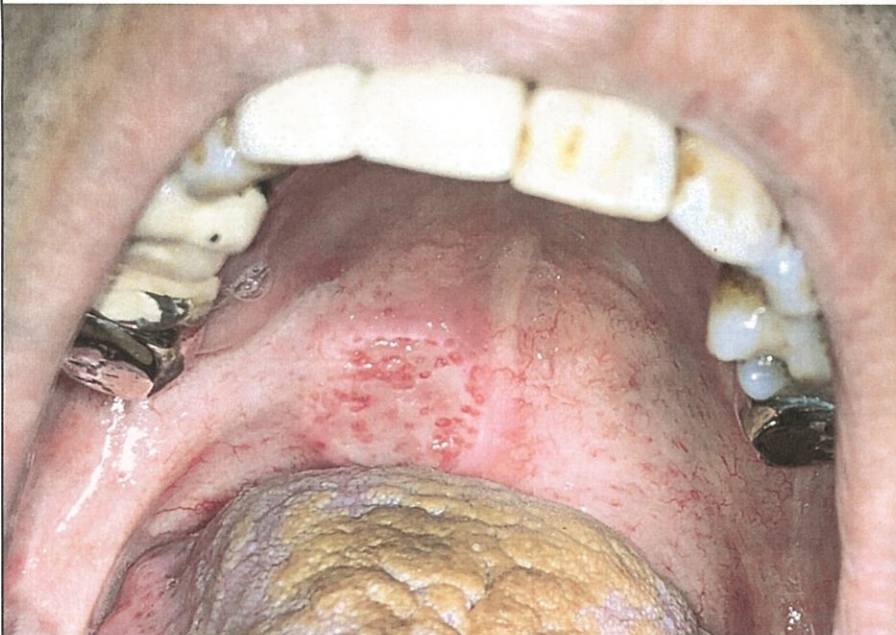

1. A 76 y/o female patient without alcohol, betel nut and cigarette smoking history. The lesion has been noted for 3 months and slightly enlarging through time. Based on the picture below, please describe the (1) differential diagnosis; (2) possible etiology; (3) treatment plan; (4) prognosis; and (5) your opinion about the current biopsy site is correct or not. (20 points)

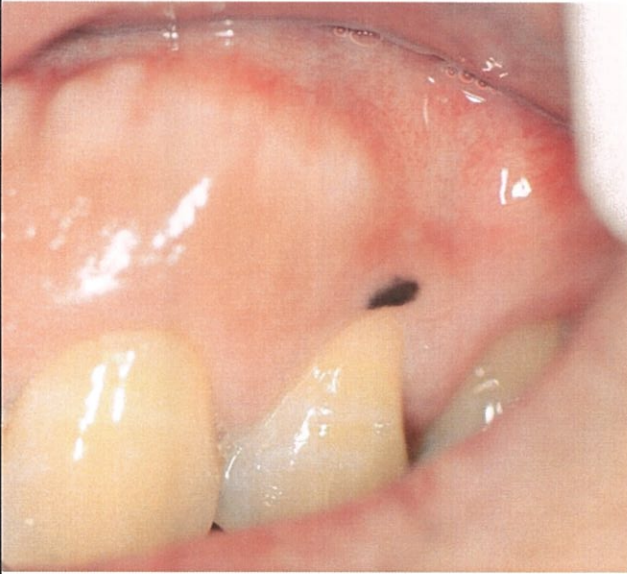


2. A 57y/o male patient has smoking history. He complained of painful sensation at right side soft palate for 3 weeks. Based on the picture below, please describe the (1) differential diagnosis; (2) possible etiology; (3) treatment plan; (4) prognosis. (20 points)

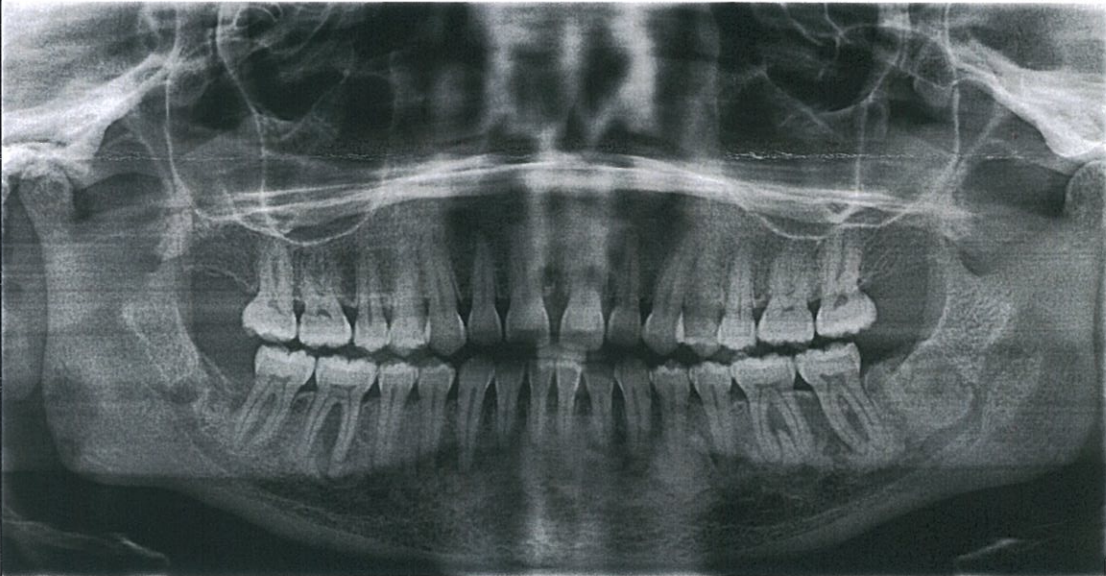

見背面

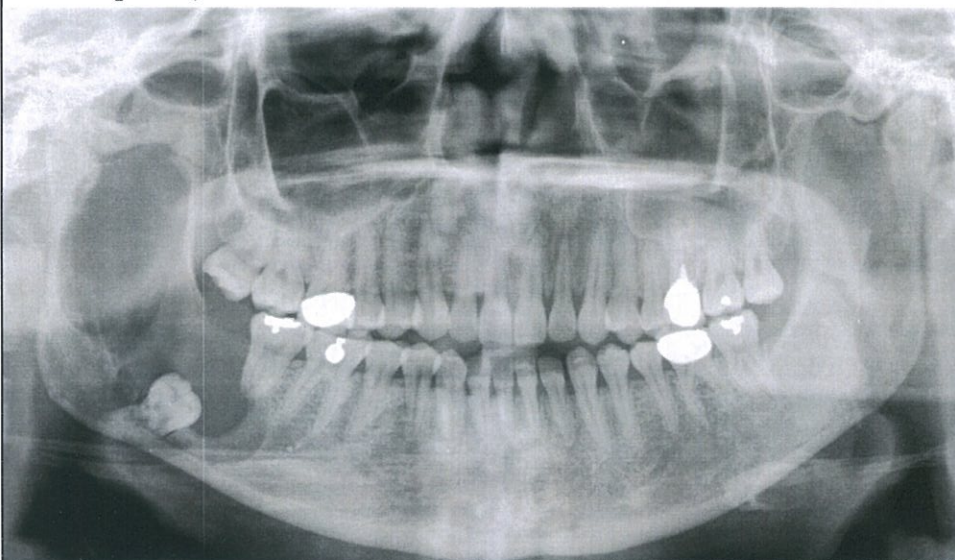3. A 43y/o male patient noted the black lesion at tooth 24 cervical gingiva for one month and he stated the lesion seemed to be enlarging recently. Based on the picture below, please describe the (1) differential diagnosis; (2) possible etiology; (3) treatment plan; (4) prognosis. (20 points)



4. A 45y/o female patient came for routine dental check-up. The panoramic x-ray was shown below. Based on the picture below, please describe the (1) differential diagnosis; (2) possible etiology; (3) treatment plan; (4) prognosis. (20 points)



5. A 25y/o male patient complained of swelling at right side of mandible. The panoramic x-ray was shown below. Based on the picture below, please describe the (1) differential diagnosis; (2) possible etiology; (3) treatment plan; (4) prognosis. (20 points)



試題隨卷繳回